

## Basal Lamellar Drusen Caused by Compound Heterozygous Variants in the *CFH* Gene

Camiel J.F. Boon,<sup>1</sup> B. Jeroen Klevering,<sup>1</sup> Carel B. Hoyng,<sup>1</sup> Marijke N. Zonneveld-Vrieling,<sup>2</sup> Sander B. Nabuurs,<sup>3</sup> Ellen Blokland,<sup>2</sup> Frans P.M. Cremers,<sup>2</sup> and Anneke I. den Hollander<sup>2,\*</sup>

Age-related macular degeneration (AMD) is a multifactorial disease that is strongly associated with the Tyr402His variant in the complement factor H (*CFH*) gene. Drusen are hallmark lesions of AMD and consist of focal-inflammatory and/or immune-mediated depositions of extracellular material at the interface of the retinal pigment epithelium (RPE) and the Bruch membrane. We evaluated the role of *CFH* in 30 probands with early-onset drusen and identified heterozygous nonsense, missense, and splice variants in five families. The affected individuals all carried the Tyr402His AMD risk variant on the other allele. This supports an autosomal-recessive disease model in which individuals who carry a *CFH* mutation on one allele and the Tyr402His variant on the other allele develop drusen. Our findings strongly suggest that monogenic inheritance of *CFH* variants can result in basal laminar drusen in young adults, and this can progress to maculopathy and severe vision loss later in life.

Age-related macular degeneration (AMD) (MIM 603075) is the most common cause of blindness in the Western world, with a prevalence of 12% after 80 years of age.<sup>1</sup> The presence of macular and/or extramacular drusen is an important risk factor for the development of advanced AMD.<sup>2</sup> Different clinical subtypes of drusen have been described, but all drusen appear to be similar on the level of ultrastructural and molecular composition.<sup>3</sup> AMD is a multifactorial disorder, and variants in several genes have been shown to be associated with the disease.<sup>1,4</sup> Strong association is seen with the Tyr402His variant and several noncoding variants in the complement factor H (*CFH*) gene (MIM 134370).<sup>5–9</sup> The *CFH* protein has been detected in drusen and acts as an inhibitor of the alternative complement cascade.<sup>10</sup>

“Basal laminar drusen” (also termed “cuticular drusen” or “early adult onset, grouped drusen”) refers to an early-onset-drusen phenotype that shows a pattern of uniform small (25 to 75  $\mu\text{m}$ ), slightly raised, yellow subretinal nodules randomly scattered in the macula. The term “basal laminar drusen” is widely used but may be considered a misnomer because these deposits do not appear to correspond with nodular or diffuse thickenings of the Bruch membrane.<sup>3</sup> In later stages, these drusen often become more numerous, with clustered groups of drusen scattered throughout the retina. On fluorescein angiography, a typical “stars-in-the-sky” picture may be observed (Figure 1).<sup>11</sup> In time, these small basal laminar drusen may expand and ultimately lead to a serous pigment epithelial detachment of the macula, which may result in visual loss.<sup>11</sup> The basal-laminar-drusen phenotype has an even stronger association with the Tyr402His variant than AMD, with an allele frequency of 70%, compared to 55% in a cohort of typical AMD patients and 34% in controls.<sup>12</sup> Basal laminar drusen

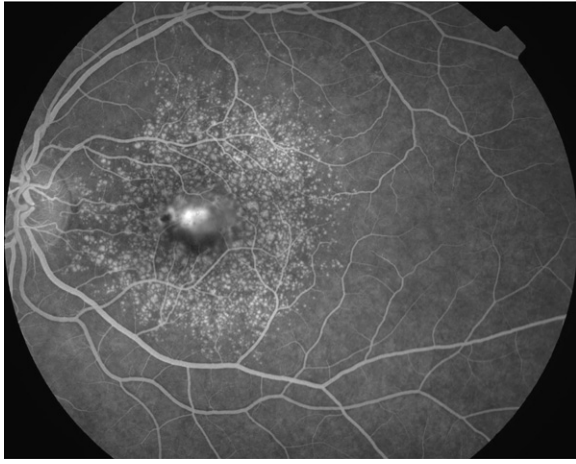
are also seen in patients with membranoproliferative glomerulonephritis type II (MPGN-II, MIM 609814), a severe early-onset renal disease caused by an uncontrolled systemic activation of the alternative pathway of the complement cascade, which can be caused by highly penetrant recessive mutations in the *CFH* gene.<sup>13,14</sup> MPGN-II associated drusen appear to be morphologically and compositionally similar to drusen in AMD.<sup>15</sup> Mutations in *CFH* have also been associated with atypical hemolytic uremic syndrome (aHUS, MIM 235400), a severe disease frequently leading to end-stage renal failure.<sup>16,17</sup>

In this study, we evaluated 30 probands diagnosed with basal-laminar-drusen maculopathy. At early stages, the diagnosis was based on the observation of small yellow-white deposits (“basal laminar drusen” or “cuticular drusen”) in the macula, sometimes extending toward the (mid-) peripheral retina, in combination with a “stars-in-the-sky” appearance on fluorescein angiography (Figure 1). The occurrence of confluent (“soft”) drusen of variable size in the central macular region and the subsequent development of a serous detachment of the retina and/or retinal pigment epithelium (RPE) were considered typical for the later stages of this disorder. A final feature in the later stages is the geographic atrophy of the RPE that is frequently observed after resolution of the detachment. An overview of the clinical characteristics of these patients is given in Tables 1 and 2. Four patients did not experience visual complaints prior to the diagnosis (the finding of retinal abnormalities was coincidental), whereas 26 patients had noticed a decrease in visual acuity, with an age at onset ranging from 35 to 70 yr (mean, 50 yr). Eight patients reported family members with macular disease or visual disturbances compatible with macular disease. In 12 patients (40%), small drusen were seen in the (mid-) peripheral

<sup>1</sup>Department of Ophthalmology, Radboud University Nijmegen Medical Centre, 6525 GA Nijmegen, The Netherlands; <sup>2</sup>Department of Human Genetics, Nijmegen Centre for Molecular Life Sciences, Radboud University Nijmegen Medical Centre, 6525 GA Nijmegen, The Netherlands; <sup>3</sup>Centre for Molecular and Biomolecular Informatics, Radboud University Nijmegen, 6525 GA Nijmegen, The Netherlands

\*Correspondence: a.denhollander@antrg.umcn.nl

DOI 10.1016/j.ajhg.2007.11.007. ©2008 by The American Society of Human Genetics. All rights reserved.



**Figure 1. Fluorescein Angiogram of the Basal-Laminar Drusen Phenotype**

Typical fluorescein angiogram of a patient with advanced drusen maculopathy resembling basal laminar drusen (patient 9). Note the typical “stars-in-the-sky” appearance, with central confluence of drusen and the small pseudovitelliform pigment epithelial detachment.

retina. In 28 patients (93%), the development of large, exudative drusen could be observed in the central macular area. A pseudovitelliform, yellow, serous retinal or RPE detachment of the central macula with associated loss of visual acuity was seen in eight patients (27%). Ten patients (33%) showed chorioretinal atrophy of the macula. During fluorescein angiography, individual drusen as well as the larger exudative drusen were hyperfluorescent. Choroidal neovascularization was seen in eight eyes of five patients.

We evaluated the role of *CFH* in the 30 probands by sequence analysis of the 22 coding exons and splice junctions. The Tyr402His variant was present in 48% of *CFH* alleles (Tables 1 and 2), which is lower than the 70% reported elsewhere in patients with basal laminar drusen,<sup>12</sup> but higher than in healthy control subjects (34%). More importantly, we found that seven patients in two families (A and B) were compound heterozygous for the nonsense mutation Gln408X and the AMD risk allele Tyr402His (Figure 2). The *CFH* variants in the deceased individual A-II.3 were deduced upon CA-marker analysis in the right branch of family A. Clinical characteristics of affected family members are shown in Figure 3 and Table 2. Two family members (A-IV.1 and A-IV.2) carrying only the Gln408X allele did not develop drusen.

In a third family (C), we identified three individuals with drusen who carried a heterozygous variant (Arg1078Ser) on one allele and the Tyr402His variant on the other allele (Figure 2). The Arg1078Ser variant occurs in the 18<sup>th</sup> short consensus repeat (SCR18) of *CFH*. To predict the effect of this variant, we constructed a homology model for SCR18 (Figure 4). Because SCR18 shares 40% homology with SCR19, model building was straightforward with the SCR19-20 structure used as a template.<sup>18</sup> The

model shows that Arg1078 is solvent exposed, and the change to serine at this position is not expected to have a large structural effect on SCR18 itself. However, SCR18 neighbors the C-terminal SCR domains 19 and 20, which were shown to have many different interaction partners, including the major opsonin C3b, glycosaminoglycans, and endothelial cells. The Arg1078Ser variant introduces a smaller side chain in SCR18 and abolishes the negative charge at this position. This change might interfere with the different interactions in which *CFH* participates. Notably, mutation of a nearby residue (Gln1076Glu) was identified in a patient with aHUS (*FH* aHUS mutation database).

In patient D, we identified the Tyr402His variant homozygously, and a heterozygous variant was identified in the splice-donor site of exon 3 (c.350+6T→G) (Figure 2). This variant is predicted to severely affect splicing, given that the splice prediction score is reduced from 0.97 to 0.59 (NNSPLICE version 0.9).<sup>19</sup> Moreover, this residue is completely conserved between human and all species for which the genomic sequence of *CFH* is available (rhesus macaque, mouse, rat, dog, horse, opossum, platypus, and elephant). The deceased mother of patient D was diagnosed with macular and peripheral drusen by a local ophthalmologist at the age of 43.

A patient in a fifth family (E) carried a heterozygous amino acid variant (Arg567Gly) and was heterozygous for the Tyr402His variant (Figure 2). Other family members were unavailable for examination or segregation analysis. The Arg567Gly variant occurs in the interdomain hinge region between the short consensus repeats SCR9 and SCR10. Because no experimental structure of SCR 9-10 is known, we built a homology model of this hinge region and the two surrounding domains by using the crystal structure of the *CFH* SCR domains 19-20 as a template.<sup>18</sup> In our model, Arg567 is located on the protein surface, and hydrogen bonds from the hinge region to the backbone of SCR10 (Figure 4). As such, Arg567 could play a structural role in defining the orientation of SCR9 with respect to SCR10. This hypothesis is supported by Glu566 and Glu568, which hydrogen bond to a tyrosine residue in SCR9 and SCR10, respectively. Given that the charged Arg567 in our model also appears to be partially exposed to the surface, it could play a role in one of the many interactions in which *CFH* can engage. For example, *CFH* has been shown to bind complement factor C3b via interaction sites in SCR domains 1–4, 9, 12–14, 19, and 20.<sup>20,21</sup> Furthermore, *CFH* can bind C-reactive protein (CRP) via SCR7 but also in the region spanning SCR8-11.<sup>22</sup> This would place Arg567 close to a C3b-binding site and in a CRP-binding region. Arg567-Gly removes a positive charge in the interdomain hinge region between SCR9 and SCR10, and is likely to result in an increased mobility of the linker between these repeats. On the basis of these findings, we speculate that Arg567Gly might result in an altered affinity of *CFH* for C3b and possibly also CRP.

**Table 1. Clinical Characteristics of Drusen Patients without Compound Heterozygous *CFH* Mutations**

Patient Number	Sex	Family History <sup>a</sup>	Age at Onset <sup>b</sup>	Age	Visual Acuity <sup>c</sup>		Retinal Phenotype <sup>d,e</sup>	CFH Variants	CFH Tyr402His
					OD	OS			
1	F	no	-	53	20/20	20/20	ODS: extensive macular drusen	-	Tyr/Tyr
2	F	no	-	40	20/20	20/20	ODS: extensive confluent macular drusen	-	Tyr/His
3	F	no	53	54	20/70	20/50	ODS: numerous small drusen in posterior pole	-	Tyr/His
4	M	no	51	57	20/70	20/70	ODS: macula: confluent drusen surrounded by small drusen, PED, chorioretinal atrophy, many small drusen in peripheral retina	-	Tyr/His
5	F	no	49	50	20/32	20/70	ODS: extensive confluent and atrophic drusen of the posterior pole, PED, OD: occult CNV, OS: minimally classic CNV	-	His/His
6	F	no	35	35	20/20	20/20	ODS: many drusen throughout (mid-) peripheral retina, confluent drusen in posterior pole	-	Tyr/Tyr
7	F	yes	44	47	20/32	20/32	OD: confluent drusen with large exudative PED and large occult exudative CNV, OS: large confluent drusen with surrounding small drusen	-	Tyr/His
8	M	no	45	58	20/25	20/100	ODS confluent macular drusen and chorioretinal atrophy	-	Tyr/His
9	F	no	43	46	20/25	20/25	ODS confluent macular drusen, PED (Figure 1)	-	Tyr/His
10	F	no	43	57	20/125	20/200	ODS: very extensive atrophic, confluent macular drusen and (mid-) peripheral drusen, OD: chorioretinal atrophy, exudative CNV OS: fibrotic scar	-	Tyr/His
11	F	no	53	54	20/20	20/25	ODS: confluent macular drusen, small midperipheral drusen	-	Tyr/His
12	M	no	50	54	20/32	20/20	ODS: confluent macular drusen, small midperipheral drusen	-	Tyr/His
13	M	no	48	60	20/32	20/250	ODS: confluent macular drusen, PED	-	Tyr/His
14	F	no	57	57	20/32	20/25	ODS: extensive confluent macular drusen, pseudovitelliform PED	-	Tyr/His
15	M	no	70	74	20/25	20/25	ODS: confluent macular drusen	-	Tyr/Tyr
16	F	no	43	56	20/20	20/20	ODS: extensive drusen in posterior pole, confluent macular drusen	-	Tyr/His
17	F	no	44	44	20/25	20/100	ODS: extensive drusen in posterior pole, confluent macular drusen	-	His/His
18	M	no	56	58	20/25	20/160	OD: confluent macular drusen, OS: macular drusen, large pseudovitelliform PED	-	Tyr/His
19	F	no	43	43	20/25	20/100	ODS: confluent macular drusen	-	Tyr/His
20	F	no	-	38	20/20	20/20	ODS: large confluent drusen in posterior pole and midperipheral retina, macular pigmentary changes	-	Tyr/His
21	F	yes	51	51	20/40	20/2000	ODS: extensive macular and (mid-) peripheral drusen, confluent macular drusen and chorioretinal atrophy	-	Tyr/His
22	F	no	-	69	20/20	20/20	ODS: confluent macular drusen with parafoveal chorioretinal atrophy	-	Tyr/His
23	F	no	47	48	20/80	20/80 (A)	ODS: extensive confluent macular drusen, numerous small (mid-) peripheral drusen, OD: large occult CNV	-	Tyr/His
24	F	yes	44	45	20/32	20/20	ODS: innumerable drusen throughout retina, confluent macular drusen	Asn1050Tyr	Tyr/His
25	F	?	62	63	20/50	20/30	ODS: confluent macular drusen and geographic atrophy, innumerable (mid-) peripheral drusen, patches of chorioretinal atrophy, reticular pattern of hyperpigmentation	Glu936Asp	Tyr/His

<sup>a</sup> A positive family history was defined as reported family members with macular disease.

<sup>b</sup> "-" indicates no visual loss reported.

<sup>c</sup> "A" denotes amblyopia.

<sup>d</sup> "PED" denotes pigment epithelial detachment.

<sup>e</sup> "CNV" denotes choroidal neovascularization.

**Table 2. Clinical Characteristics of Drusen Patients and Family Members Carrying Compound Heterozygous *CFH* Mutations**

Patient Code <sup>a</sup>	Sex	Family History <sup>b</sup>	Age at Onset <sup>c</sup>	Age	Visual Acuity <sup>d</sup>		Retinal Phenotype <sup>e,f</sup>	CFH Variant	CFH Tyr402His
					OD	OS			
A-III.5 (P)	M	yes	45	62	20/400	20/25	OD: confluent macular drusen, chorioretinal atrophy, (mid-) peripheral retina: cystoid drusen, chorioretinal atrophy (Figure 3A,B) OS: confluent macular drusen, (mid-) peripheral retina: cystoid drusen, chorioretinal atrophy (Figure 3C,D)	Gln408X	Tyr/His
A-II.3	M	yes	?	deceased	20/25	20/200	ODS: extensive confluent drusen and chorioretinal atrophy	Gln408X	Tyr/His
A-III.1	F	yes	63	83	20/800	20/800	ODS: chorioretinal atrophy of posterior pole, large atrophic drusen, subretinal fibrosis, extensive drusen in atrophic (mid-) peripheral retina	Gln408X	Tyr/His
A-III.3	M	yes	67	81	20/50	20/400	ODS: confluent atrophic macular drusen and chorioretinal atrophy, extensive drusen in (mid-) peripheral retina	Gln408X	Tyr/His
A-IV.1	F	yes	-	50	20/20	20/20	ODS: normal	Gln408X	Tyr/Tyr
A-IV.2	F	yes	-	48	20/20	20/20	ODS: normal	Gln408X	Tyr/Tyr
B-II.1 (P)	M	yes	48	51	20/25	20/25	ODS: confluent macular drusen, (mid-) peripheral retina: small drusen and discrete pigmentary changes (Figure 4E-H)	Gln408X	Tyr/His
B-I.2	F	yes	68	85	20/400	20/32	ODS: confluent macular drusen and chorioretinal atrophy, (mid-) peripheral retina: small drusen and discrete pigmentary changes	Gln408X	Tyr/Tyr
B-III.1	M	yes	-	25	20/20	20/20	ODS: very discrete midperipheral cystoid drusen, clearly visualized on fluorescein angiography	Gln408X	Tyr/His
B-III.2	M	yes	-	22	20/20	20/20	ODS: barely discernable macular and peripheral drusen, clearly visualized on fluorescein angiography (Figure 4I,J)	Gln408X	Tyr/His
C-II.2 (P)	M	yes	57	65	20/40	20/200	ODS: innumerable small drusen throughout retina, (mid-) peripheral chorioretinal atrophy and reticular pattern of hyperpigmentation, OD: large confluent macular drusen, PED, occult CNV, chorioretinal atrophy, OS: atrophic scar in macula, surrounded by large confluent drusen	Arg1078Ser	Tyr/His
C-II.3	F	yes	-	64	20/25	20/25	ODS: confluent macular drusen and PED, numerous small drusen in (mid-) peripheral retina	Arg1078Ser	Tyr/His
C-II.5	M	yes	-	56	20/16	20/16	ODS: barely discernable (mid-) peripheral drusen, clearly visualized on fluorescein angiography	Arg1078Ser	Tyr/His
D	M	yes	54	54	20/20	20/125 (A)	ODS: large confluent macular drusen, cystoid drusen in midperipheral retina	c.350+6T→G	His/His
E	F	yes (aunt)	54	55	20/32	20/70	ODS: confluent macular drusen surrounded by small drusen, PED, chorioretinal atrophy, small drusen in peripheral retina	Arg567Gly	Tyr/His

<sup>a</sup> "P" denotes proband.

<sup>b</sup> A positive family history was defined as reported family members with macular disease.

<sup>c</sup> "-" indicates no visual loss reported.

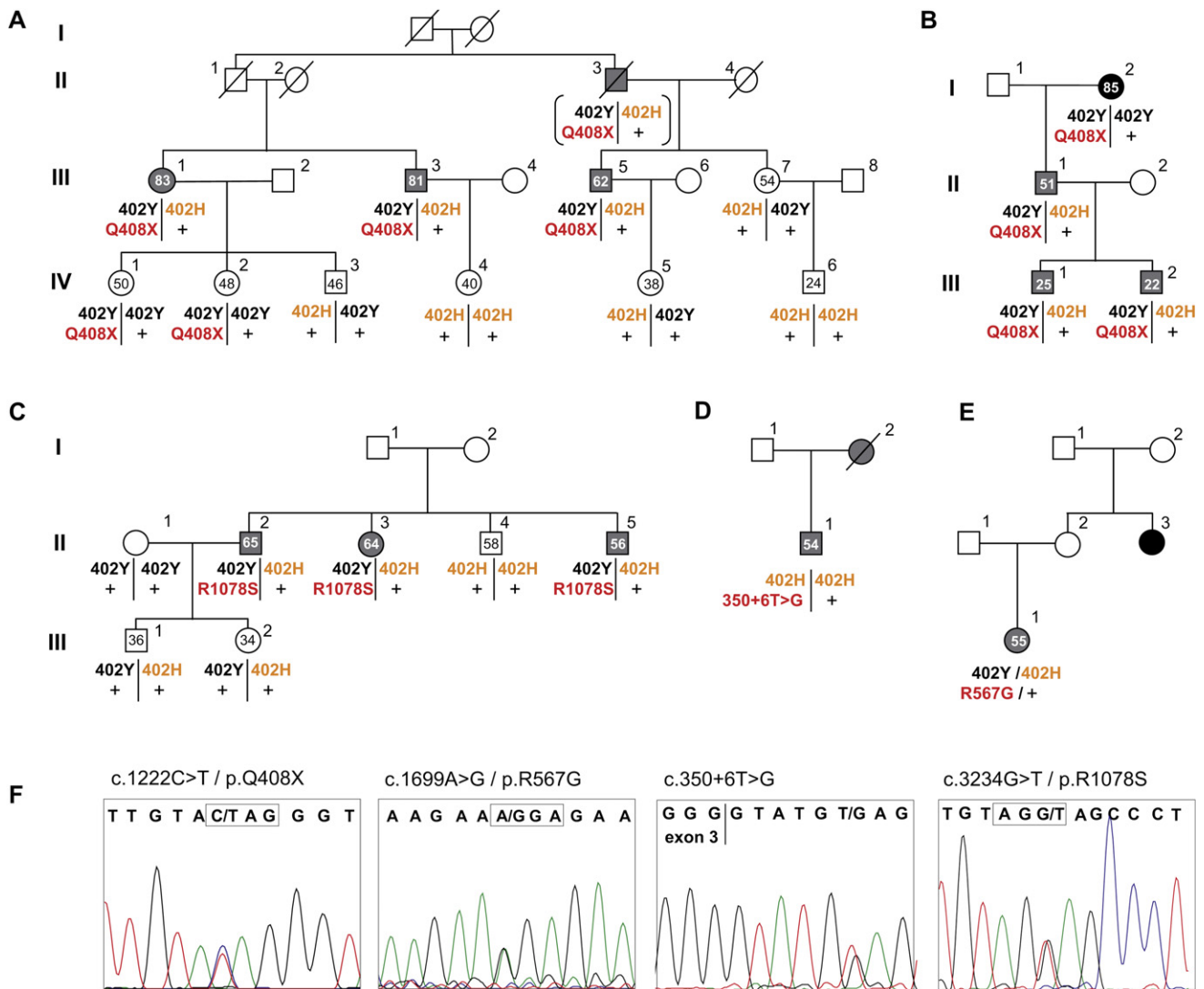
<sup>d</sup> "A" denotes amblyopia.

<sup>e</sup> "CNV" denotes choroidal neovascularization.

<sup>f</sup> "PED" denotes pigment epithelial detachment.

The new *CFH* variants identified in these families were not identified in 92 ethnically matched control subjects, nor in 90 controls between 65 and 85 years of age who did not have any signs of maculopathy. In two other pa-

tients, we identified Asn1050Tyr and Glu936Asp heterozygously. The Asn1050Tyr variant was previously found in 4% of control alleles,<sup>16</sup> and the Glu936Asp variant was found in 18% of controls.<sup>23</sup> Although proband 24 in our



**Figure 2. Molecular Genetic Analysis of the *CFH* Gene in Families Affected with Drusen Maculopathy**

(A and B) Seven affected individuals in two families are compound heterozygous for the nonsense mutation Gln408X and the AMD risk allele Tyr402His. Brackets flanking the *CFH* variants of A-I.3 indicate that they were deduced through CA-marker analysis.

(C) Three affected individuals in a third family are compound heterozygous for the missense variant Arg1078Ser and Tyr402His.

(D) Patient D is homozygous for the Tyr402His variant, and in addition, he carries a heterozygous variant in the splice-donor site of exon 3 (c.350+6T→G).

(E) A patient in a fifth family carries a heterozygous amino acid variant (Arg567Gly) and is heterozygous for the Tyr402His variant. Segregation analysis could not be performed.

Grey pedigree symbols denote patients with basal laminar drusen. The black symbols denote two females affected with AMD. Numbers in the pedigree symbols reflect current age.

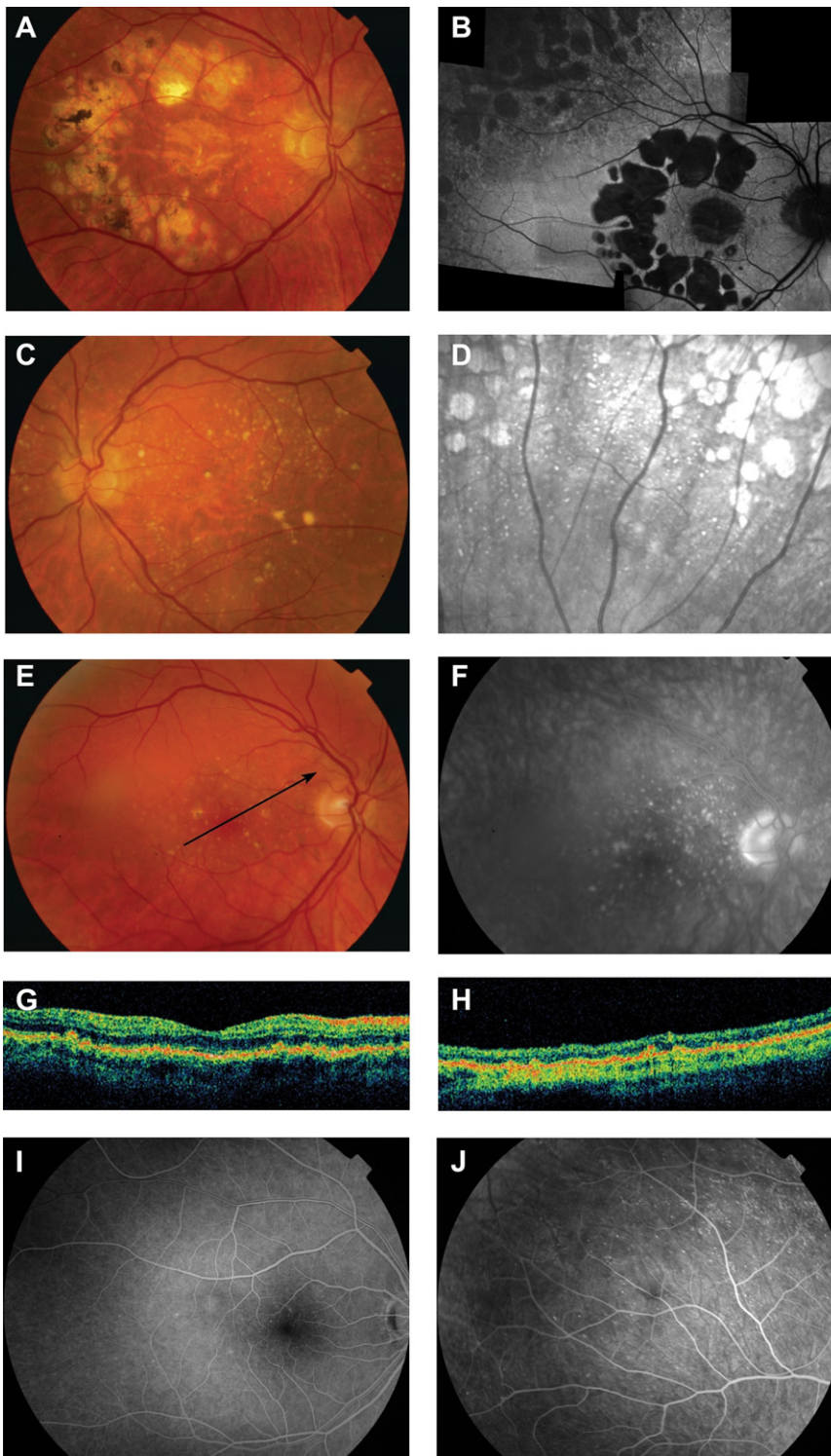
(F) Sequences of heterozygous variants detected in the *CFH* gene.

study was compound heterozygous for the Asn1050Tyr and Tyr402His alleles, his affected father carried the Asn1050Tyr variant without Tyr402His, indicating that compound heterozygosity of *CFH* variants does not cause the disease in this family.

Previous studies have shown that the Tyr402His variant in *CFH* is strongly associated with AMD and basal laminar drusen.<sup>5–7,12</sup> Our findings strongly support a recessive-disease model in a subgroup of patients with basal laminar drusen. In these families, individuals develop drusen when they carry a *CFH* mutation on one allele and the Tyr402His

variant on the other allele. The presence of a *CFH* mutation in the absence of the Tyr402His variant, however, might contribute to the development of AMD at later age (e.g., in individual B-I.2). Compound heterozygosity was confirmed in four families (A, B, C, and D), but in one family (E) segregation analysis could not be performed. Affected individuals of families A, B, C, and D presented with many small drusen with a slightly pigmented border peripheral to the vascular arcades. These peculiar drusen were most readily observed on ophthalmoscopy, fluorescein angiography, and infrared reflectance photography





**Figure 3. Retinal Phenotypes of Drusen Patients Carrying the Combination of a Gln408X Mutation and the Tyr402His AMD Risk Variant**

(A–D) Retinal phenotype of patient A-III.5. (A) Fundus photograph of the right eye, showing extensive chorioretinal atrophy of the posterior pole. At the first examination, 17 years earlier, these areas corresponded with large confluent drusen with incipient atrophy. (B) The short-wavelength fundus autofluorescence (FAF) image shows an absence of FAF corresponding with the patches of chorioretinal atrophy, not only in the macular area but also in the midperipheral retina. Moreover, diffuse changes in FAF intensity can be observed. (C) Fundus photograph of the left eye, showing large confluent drusen and mild chorioretinal atrophy. (D) An infrared reflectance photograph clearly visualizes small, round, midperipheral drusen scattered between the patches of chorioretinal atrophy. The drusen seen with infrared reflectance corresponded with the discrete, round, yellow-white drusen with a slightly pigmented border seen on ophthalmoscopy.

(E–H) Retinal phenotype of patient B-II.1. (E) Fundus photograph showing confluent macular drusen. (F) The macular drusen can be more easily detected on the fluorescein angiogram. (G) Optical coherence tomography (OCT, oblique section) showing small dome-shaped elevations of the “outer red line,” which correspond with the visible drusen on ophthalmoscopy (arrow). (H) Similar to patient A-III.5, small midperipheral drusen were seen in this patient, and OCT revealed aspects similar to the macular drusen.

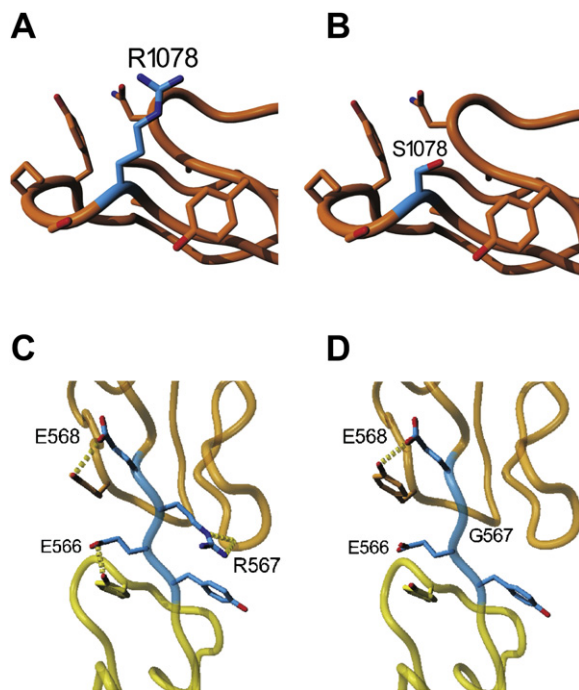
(I and J) Fluorescein angiography showed tiny hyperfluorescent drusen in the parafoveal area and in the (mid-) peripheral retina of Patient B-III.2 (the 22-year-old asymptomatic son of patient B-II.1), but the drusen were difficult to discern on ophthalmoscopy. His 25-year-old brother (B-III.1) had similar midperipheral lesions, but to a lesser extent.

(Figures 3C, 3D, and 3J). Optical coherence tomography (OCT) showed that the appearance of the drusen peripheral to the vascular arcades was similar to that of the drusen located at the macula.

Mutations in the *CFH* gene can cause severe renal failure in patients with MPGN-II and aHUS. We did not observe signs of a renal disorder with routine laboratory testing of blood and urine in the drusen patients with compound heterozygous *CFH* variants. It is possible that in these pa-

tients, the residual *CFH* activity sustains sufficient complement regulatory activity for normal renal function, whereas the ocular environment may be more sensitive to deposition and damage. Subclinical renal abnormalities, however, remain possible.<sup>24</sup>

There are a few examples in which heterozygosity for a mutation implicated in a Mendelian disorder appeared to result in an increased risk for a complex disease.<sup>25</sup> In this study, we show that monogenic inheritance of *CFH* variants can result



**Figure 4. Molecular Modeling of Missense Variants Detected in CFH**

(A and B) Model of the SCR18 domain, depicting the effect of the Arg1078Ser variant. (A) wild-type sequence (Arg1078). (B) Arg1078Ser variant.

(C and D) Model of the SCR9 and SCR10 domains, depicting the effect of the Arg567Gly variant. (C) wild-type sequence (Arg567). (D) Arg567-Gly variant. The SCR9 domain is shown in yellow, the SCR10 domain in orange, and the linker region between the two domains is shown in blue. Hydrogen-bonding partners for the residues in the linker region are indicated with dotted lines. All figures were made with Yasara.

in basal laminar drusen in young adults, and this can progress to maculopathy and severe vision loss later in life. Our findings indicate that basal laminar drusen and AMD belong to a spectrum of diseases associated with either monogenic or multifactorial inheritance of variants in the *CFH* gene.

#### Acknowledgments

We thank the involved patients for their cooperation, and J.F. Wetzels and H.G. Brunner for expert advice. These studies were supported by the Gelderse Blindenstichting, the Landelijke Stichting voor Blinden en Slechtzienden, the Rotterdamse Vereniging Blindenbelangen, the Stichting Blindenhulp, the Stichting Ondersteuning Oogheelkunde 's-Gravenhage, and the Stichting voor Ooglijders.

Received: July 9, 2007

Revised: October 23, 2007

Accepted: November 7, 2007

Published online: February 7, 2008

#### Web Resources

The URLs for data presented herein are as follows:

FH aHUS Mutation Database, <http://www.fh-hus.org/>

Online Mendelian Inheritance in Man, <http://www.ncbi.nlm.nih.gov/Omim/>

Yasara, <http://www.yasara.org>

#### References

- de Jong, P.T.V.M. (2006). Age-related macular degeneration. *N. Engl. J. Med.* 355, 1474–1485.
- Klein, R., Klein, B.E., Knudtson, M.D., Meuer, S.M., Swift, M., and Gangnon, R.E. (2007). Fifteen-year cumulative incidence of age-related macular degeneration: The Beaver Dam Eye Study. *Ophthalmology* 114, 253–262.
- Russell, S.R., Mullins, R.F., Schneider, B.L., and Hageman, G.S. (2000). Location, substructure, and composition of basal laminar drusen compared with drusen associated with aging and age-related macular degeneration. *Am. J. Ophthalmol.* 129, 205–214.
- Scholl, H.P., Fleckenstein, M., Charbel, I.P., Keilhauer, C., Holz, F.G., and Weber, B.H. (2007). An update on the genetics of age-related macular degeneration. *Mol. Vis.* 13, 196–205.
- Edwards, A.O., Ritter, R. III, Abel, K.J., Manning, A., Panhuyzen, C., and Farrer, L.A. (2005). Complement factor H polymorphism and age-related macular degeneration. *Science* 308, 421–424.
- Hageman, G.S., Anderson, D.H., Johnson, L.V., Hancox, L.S., Taiber, A.J., Hardisty, L.I., Hageman, J.L., Stockman, H.A., Borchardt, J.D., Gehrs, K.M., et al. (2005). A common haplotype in the complement regulatory gene factor H (HF1/CFH) predisposes individuals to age-related macular degeneration. *Proc. Natl. Acad. Sci. USA* 102, 7227–7232.
- Haines, J.L., Hauser, M.A., Schmidt, S., Scott, W.K., Olson, L.M., Gallins, P., Spencer, K.L., Kwan, S.Y., Noureddine, M., Gilbert, J.R., et al. (2005). Complement factor H variant increases the risk of age-related macular degeneration. *Science* 308, 419–421.
- Li, M., Atmaca-Sonmez, P., Othman, M., Branham, K.E., Khanna, R., Wade, M.S., Li, Y., Liang, L., Zarepari, S., Swaroop, A., et al. (2006). CFH haplotypes without the Y402H coding variant show strong association with susceptibility to age-related macular degeneration. *Nat. Genet.* 38, 1049–1054.
- Maller, J., George, S., Purcell, S., Fagerness, J., Altshuler, D., Daly, M.J., and Seddon, J.M. (2006). Common variation in three genes, including a noncoding variant in CFH, strongly influences risk of age-related macular degeneration. *Nat. Genet.* 38, 1055–1059.
- Mullins, R.F., Russell, S.R., Anderson, D.H., and Hageman, G.S. (2000). Drusen associated with aging and age-related macular degeneration contain proteins common to extracellular deposits associated with atherosclerosis, elastosis, amyloidosis, and dense deposit disease. *FASEB J.* 14, 835–846.
- Gass, J.D., Jallow, S., and Davis, B. (1985). Adult vitelliform macular detachment occurring in patients with basal laminar drusen. *Am. J. Ophthalmol.* 99, 445–459.
- Grassi, M.A., Folk, J.C., Scheetz, T.E., Taylor, C.M., Sheffield, V.C., and Stone, E.M. (2007). Complement factor H polymorphism p.Tyr402His and cuticular drusen. *Arch. Ophthalmol.* 125, 93–97.
- Appel, G.B., Cook, H.T., Hageman, G., Jennette, J.C., Kashgarian, M., Kirschfink, M., Lambris, J.D., Lanning, L., Lutz, H.U., Meri, S., et al. (2005). Membranoproliferative

- glomerulonephritis type II (dense deposit disease): An update. *J. Am. Soc. Nephrol.* *16*, 1392–1403.
14. Leys, A., Proesmans, W., Van Damme-Lombaerts, R., and Van Damme, B. (1991). Specific eye fundus lesions in type II membranoproliferative glomerulonephritis. *Pediatr. Nephrol.* *5*, 189–192.
  15. Mullins, R.F., Aptsiauri, N., and Hageman, G.S. (2001). Structure and composition of drusen associated with glomerulonephritis: Implications for the role of complement activation in drusen biogenesis. *Eye* *15*, 390–395.
  16. Richards, A., Buddles, M.R., Donne, R.L., Kaplan, B.S., Kirk, E., Venning, M.C., Tielemans, C.L., Goodship, J.A., and Goodship, T.H. (2001). Factor H mutations in hemolytic uremic syndrome cluster in exons 18–20, a domain important for host cell recognition. *Am. J. Hum. Genet.* *68*, 485–490.
  17. Perez-Caballero, D., Gonzalez-Rubio, C., Gallardo, M.E., Vera, M., Lopez-Trascasa, M., Rodriguez de Cordoba, S., and Sanchez-Corral, P. (2001). Clustering of missense mutations in the C-terminal region of factor H in atypical hemolytic uremic syndrome. *Am. J. Hum. Genet.* *68*, 478–484.
  18. Jokiranta, T.S., Jaakola, V.P., Lehtinen, M.J., Parepalo, M., Meri, S., and Goldman, A. (2006). Structure of complement factor H carboxyl-terminus reveals molecular basis of atypical haemolytic uremic syndrome. *EMBO J.* *25*, 1784–1794.
  19. Reese, M.G., Eeckman, F.H., Kulp, D., and Haussler, D. (1997). Improved splice site detection in Genie. *J. Comput. Biol.* *4*, 311–323.
  20. Jokiranta, T.S., Hellwage, J., Koistinen, V., Zipfel, P.F., and Meri, S. (2000). Each of the three binding sites on complement factor H interacts with a distinct site on C3b. *J. Biol. Chem.* *275*, 27657–27662.
  21. Ormsby, R.J., Griggs, K.M., Gordon, D.L., and Jokiranta, T.S. (2007). Localisation of the third and fourth C3b-binding domains in the human complement regulator factor H. *Mol. Immunol.* *44*, 224.
  22. Laine, M., Jarva, H., Seitsonen, S., Haapasalo, K., Lehtinen, M.J., Lindeman, N., Anderson, D.H., Johnson, P.T., Jarvela, I., Jokiranta, T.S., et al. (2007). Y402H polymorphism of complement factor H affects binding affinity to C-reactive protein. *J. Immunol.* *178*, 3831–3836.
  23. Caprioli, J., Castelletti, F., Bucchioni, S., Bettinaglio, P., Bresin, E., Pianetti, G., Gamba, S., Brioschi, S., Daina, E., Remuzzi, G., et al. (2003). Complement factor H mutations and gene polymorphisms in haemolytic uraemic syndrome: The C-257T, the A2089G and the G2881T polymorphisms are strongly associated with the disease. *Hum. Mol. Genet.* *12*, 3385–3395.
  24. Thompson, C.L., Klein, B.E., Klein, R., Xu, Z., Capriotti, J., Joshi, T., Leontiev, D., Lee, K.E., Elston, R.C., and Iyengar, S.K. (2007). Complement factor H and Hemicentin-1 in age-related macular degeneration and renal phenotypes. *Hum. Mol. Genet.* *16*, 2135–2148.
  25. Sidransky, E. (2006). Heterozygosity for a Mendelian disorder as a risk factor for complex disease. *Clin. Genet.* *70*, 275–282.